

We are IntechOpen, the world's leading publisher of Open Access books Built by scientists, for scientists

7,300

Open access books available

192,000

International authors and editors

210M

Downloads

Our authors are among the

154

Countries delivered to

TOP 1%

most cited scientists

14%

Contributors from top 500 universities



WEB OF SCIENCE™

Selection of our books indexed in the Book Citation Index
in Web of Science™ Core Collection (BKCI)

Interested in publishing with us?
Contact book.department@intechopen.com

Numbers displayed above are based on latest data collected.
For more information visit www.intechopen.com



Titanium: A New Allergen

Laurence Evrard

*Stomatology and Maxillo-facial Surgery Department
Hopital Erasme – ULB Brussels
Belgium*

1. Introduction

Buccal allergies represent a growing problem and often go undiagnosed by health professionals. There is an increase in the prevalence of oral allergies to dental materials, and especially to metals used in dental materials.

Titanium, used in orthopaedic devices and oral implants, although considered an inert material, can actually induce toxicity or allergic type I or IV reactions.

Cases of an allergy to titanium described in the literature reflect the difficulty in the diagnosis of this allergy. In case of a suspected contact allergy, epicutaneous patch tests can be done, which consist of applying the allergens which are to be tested to the patient's back. These tests are known to have a diagnostic efficiency of 75% for metal allergy, and can therefore underdiagnose a titanium sensitization or allergy. Blood tests which can be used for the diagnosis of allergies are based on lymphoblastic transformation. They are more sensitive than patch tests, but sometimes lack specificity.

The occurrence of an allergy to titanium could be responsible for successive unexplained cases of failure of dental implants in some patients (known as "cluster patients"). It has been reported that the risk of an allergy to titanium is increased in patients who are allergic to other metals.

In these patients, an allergy evaluation is recommended, in order to exclude any problem with titanium dental implants.

1.1 Types of allergies

The term "allergy" is used to define a specific immune reaction to one or more exogenic substances (allergens).

Four types of allergies have been described. For a review see Gell and Coombs, 1963.

Type I allergy, known as immediate sensitivity, is characterized by interactions between an allergen and IgE present on the surface of mastocytes inducing histamine and other vasoactive peptide leakage. This is sometimes associated with atopy. This type of allergy may manifest clinically by acute reaction of anaphylaxis, which can represent a life-threatening condition. Type I allergy also causes urticarial reactions on the skin, in the form of erythematous plaques or papules, accompanied by pruritus or tingling sensations.

Type II allergy, known as cytotoxic, or antibody-dependent hypersensitivity, consists of an autoimmune cytotoxic reaction involving IgG and IgM and is encountered, for example, in acute transplant rejection or autoimmune haemolytic anaemia.

Type III allergy, or immune complex disease, is due to precipitation of immune complex formed by antigen-IgG in the blood vessel walls and can induce vasculitic lesions, manifesting in the form of the Arthus reaction, glomerulonephritis associated with streptococcal throat infection or systemic lupus erythematosus.

Type IV allergy, known as delayed-type hypersensitivity, or cell-mediated immune memory response, antibody-independent or contact allergy, is by far the most frequent type of allergy. It is defined as a cell-mediated delayed sensitization reaction (mediated by Langerhans cells and T-lymphocytes), and occurs after exposure to allergens for between ten days and several years. Type IV sensitization is induced by repeated contact of an allergen with skin or mucosa, and follows several steps (Figure 1). In the first step, a hapten penetrates through the skin or through the epithelium of the mucosa, and combines with endogenous proteins to form an antigenic molecule: the allergen. This allergen is captured by the Langerhans cells, which present it to the T-lymphocytes, which become sensitized and thereafter carry on their surface a specific receptor to the allergen. These lymphocytes are known as “memory lymphocytes”, and are able to recognize the allergen. Following another contact, the allergen binds to the specific receptor of the memory lymphocytes, which multiply and produce a set of cytokines. An allergic cellular inflammatory reaction takes place within 48 to 72 hours, and is responsible for the clinical manifestations of type IV allergy (Axell, 2001, Grevers and Röcken, 2002, Gawrodger, 2005). Type IV allergy is more frequently encountered in the skin than in the oral mucosa. This has been explained by the fact that Langerhans cells are about ten times more numerous in the layers underlying the skin than in those underlying the oral mucosa. Another reason is the rich network of capillary vessels which characterizes oral mucosa vascularization and which, in turn, eliminates the allergens more quickly from the area (Forte et al, 2008). Clinically, it may manifest as chronic transplant rejection, or more often as chronic dermatitis (eczema).

Allergy types I, III and IV may manifest in the orofacial region (Axell, 2001, Grevers, 2002, Gawrodger, 2005).

A hapten penetrates skin or mucosa and combines with endogenous proteins to form an allergen. Langerhans cells capture the allergen, and present it to the T-lymphocytes, which become sensitized and thereafter carry on their surface a specific receptor to the allergen. These lymphocytes are known as “memory lymphocytes”.

1.2 Clinical manifestations of an allergy in the orofacial region

Patients with an oral allergy complain of various symptoms such as burning or tingling sensations, with or without swelling, oral dryness or loss of taste (Garhammer et al, 2001, Lygre et al, 2003, Gawrodger 2005), or sometimes more general symptoms such as headache, dyspepsia, asthenia, arthralgia, myalgia (Lygre et al, 2003, Vamnes et al, 2004).

The signs of an oral allergy include erythema of the oral mucosa, labial oedema or purpuric patches on the palate, mouth ulcers, hyperplastic gingivitis, areas of depapillation on the tongue, angular cheilitis, perioral eczematous eruption, or lichenoid reactions localized on the oral mucosa (Alanko et al, 1996, Leigh et al, 2001, Vamnes et al, 2004).

Type I allergy may manifest clinically in the orofacial region, in the acute form by Quincke's oedema, characterized by swelling, which, if it involves the upper respiratory tract, can become life-threatening for the patient. In serious forms, it gives rise to urticarial reactions and/or tingling sensations or pruritus, localized in the oral or pharyngeal cavity (Axell, 2001, Grevers and Röcken, 2002, Gawrodger, 2005).

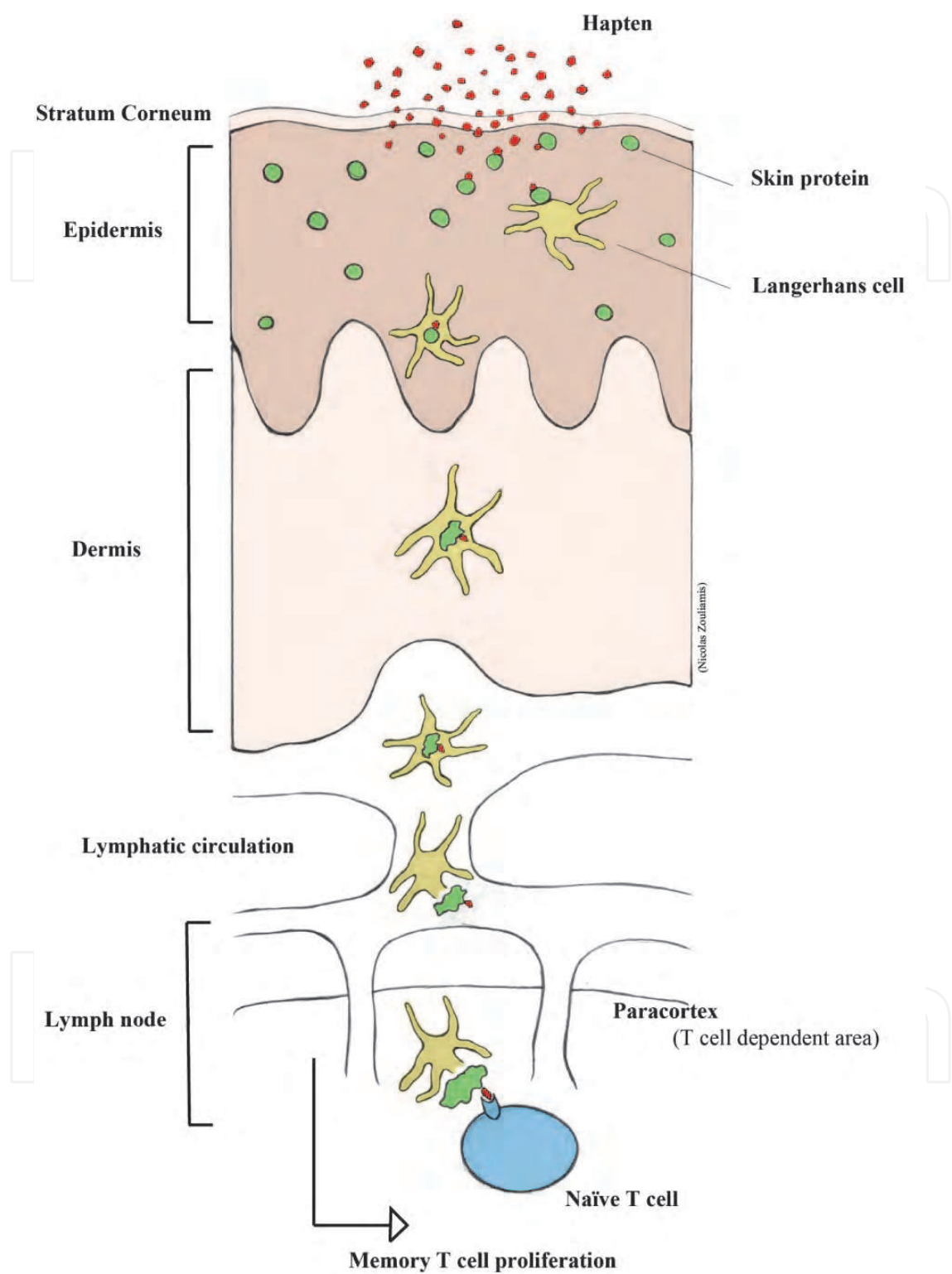


Fig. 1. Development of type IV sensitivity.

Type III allergy in the buccal area can take the form of aphthous ulcerations of the oral mucosa or, in more serious cases, the form of erythema multiforme, with large ulcerations of

the oral mucosa found in association with typical skin lesions “en cocarde” (Axell, 2001, Grevers and Röcken, 2002, Gawrodger, 2005).

Type IV allergy is by far the most frequent allergy encountered in the orofacial region (Gawrodger, 2005). This type IV allergy may manifest clinically by eczema, angular cheilitis, cheilitis (Figure 2), erythema of the oral mucosa, hyperplastic gingivitis (Figure 3), lichenoid reactions of the oral mucosa (Figure 4), perioral dermatitis or a loss of lingual papillae that can mimic “geographical tongue” (Waroquier et al, 2009) (Figure 5) (Vamnes et al., 2004, Leigh et al., 2001, Alanko et al., 1996). Clinical lesions are generally localized next to structures containing the allergen, as illustrated by lichenoid reactions just in front of amalgam fillings containing mercury (Figure 6), or the mucosa of the palate next to a prosthesis containing methacrylate resin (Figure 7) (Evrard and Parent, 2010).

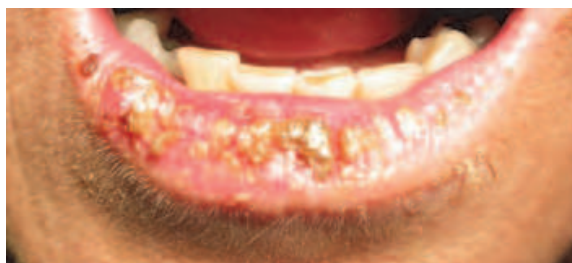

Fig. 2. Contact cheilitis in a patient who has developed an allergy to a component of her lipstick.

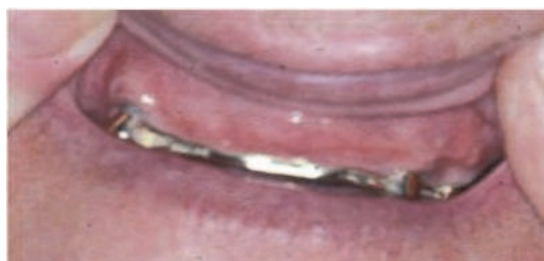

Fig. 3. Hyperplastic gingivitis associated with a contact allergy to gold. There is a prosthetic gold bar in the upper jaw.

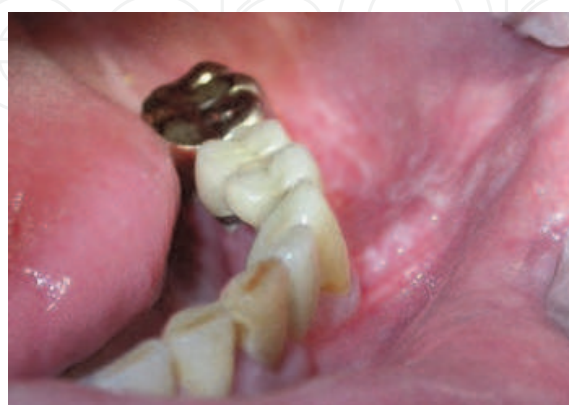

Fig. 4. Lichenoid reaction of the oral mucosa, associated with a contact allergy to gold. The patient has a gold crown on tooth 36.

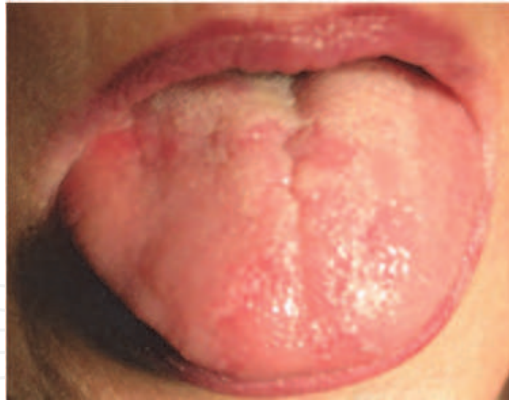

Fig. 5. Depapillation of the tongue, mimicking a geographical tongue, associated with a contact allergy to mercury and gold.

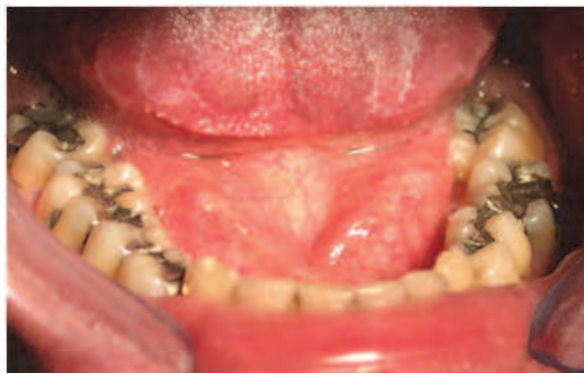

Fig. 6. Lichenoid reactions on the mucosa of the tongue, associated with a contact allergy to mercury. The patient has amalgam filling in his teeth.

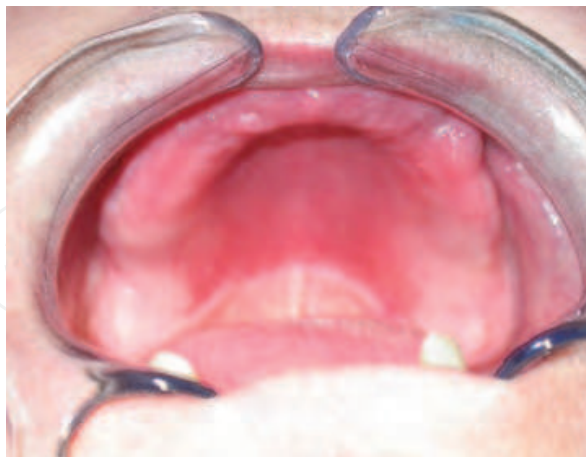

Fig. 7. Erythema of the palate in the area in contact with a resin prosthesis, in association with a contact allergy to methyl methacrylate.

In type IV allergy, patients complain of burning or tingling sensations of the oral mucosa, sometimes of dryness of the mouth, or a metallic taste (Lygre et al., 2003, Gawkrödger, 2005). Burning sensations ("burning mouth") can reach a frequency of 72% in patients with a contact allergy to dental materials (Garhammer et al, 2001, Waroquier et al, 2007). Other

causes can give rise to the same signs and symptoms as those found in allergy; in such cases it is necessary, when faced with burning sensations and/or erythematous patches on the oral mucosa, to exclude metabolic causes such as iron, B12 or folate deficiency by doing a blood test, and to rule out the possibility of a fungal infection, taking a swab of the lesion and culturing it, before going on to allergy testing.

1.3 Diagnostic tests for allergy

The diagnosis of a contact/type IV allergy is typically based on the patient's medical record, clinical findings and the results of epicutaneous tests.

Epicutaneous tests are known as "patch tests". The principle is to apply different allergens which are to be tested on the patient's back. The results are read after 48 and 72 hours for most allergens, and also after 10 days for gold testing (because gold can give rise to late reactions). If the test is positive for an allergen, the area of skin corresponding to the tested allergen will show an eczematous reaction: erythema and/or vesicles and pruritus (Alanko et al, 1996, Grevers and Röcken, 2002, Gawrodger, 2005). There is a limit to the utility of patch tests, given their poor sensitivity, which has been shown to be about 75% for type IV metal allergy (Forte et al, 2008). Some authors report a lack of standardization in the patch tests, especially for allergens such as titanium (Fischer, 2008, Forte et al, 2008). According to these authors, patch tests have been validated only for dermal sensitization to allergens, and their relevance for systemic sensitization to allergens such as titanium (mucosal and internal) is limited.

Thus, patch test may underestimate the real prevalence of a metal allergy.

Skin tests (prick tests) help in the diagnosis of a type I allergy. They consist of intradermal inoculation of the antigen (Yamauci et al, 2000). The results are read within 15 to 30 minutes. If the test is positive, there will be a red, papular and/or vesicular reaction of the skin. Prick tests are not routinely done for the diagnosis of an oral allergy to a dental material, because most of the reactions to dental material are Type IV. Nevertheless, prick tests are used in the diagnosis of a food allergy, which may manifest by aphthous lesions of the oral mucosa (Scully, 2004).

A blood test can help in the diagnosis of a type IV allergy. *In vitro* testing with the lymphocyte transformation test (LTT) can detect both dermally and non-dermally (mucosal) sensitizing allergens. It has been used to detect hypersensitivity leading to both local and systemic effects resulting from dental allergies, in particular in the optimized version of LTT known as MELISA (Stjekstal et al, 1994, Muller and Valentine-Thon, 2006). The patient's lymphocytes are exposed to the allergen to be tested. If they have previously been sensitized to the allergen, they will undergo proliferation, which is measured using incorporation of radioactive nucleotides (tritiated thymidine). Some authors have reported that non-relevant proliferation of lymphocytes could happen in non-sensitized patients (Fisher's, 2008), leading to some false-positive results.

It would be valuable in the future to have a test that would respond with good sensitivity and good specificity, thus providing a better diagnostic tool.

2. Allergy to dental materials

There are various dental materials that have been shown to be capable of triggering an allergic reaction in the oral cavity, and contain metals (nickel, cobalt, chromium, gold, palladium, mercury), fragrances (balsam of Peru, fragrance mix, eugenol, cinnamic

aldehyde, essential oils), topical medicines (including some synthetic steroids), preservatives, resins, colourings and other products contained in toothpastes (Lesueur and Lannias, 2003, Evrard and Parent 2010).

It has been shown that dental materials can give rise to type I, type III or type IV hypersensitivity. In type IV allergy, which is by far the most frequent type encountered in the oral cavity, signs and symptoms can appear between a few days and several years after the beginning of contact with the allergen (Gawrodger 2005, Vamnes et al, 2004, Garhammer et al, 2001, Lesueur and Yiannias, 2003, Evrard and Parent, 2010).

2.1 Dental metals involved in oral allergy

In the field of dentistry, dental metals are used in precious and non-precious alloys, for producing removable or fixed prostheses, or dental fillings. Titanium is used for its excellent biocompatibility in implantology and maxillo-facial surgery and will be the subject of Chapter 3.

Metals contained in dental alloys may corrode in an electrolytic solution such as saliva. Corrosion will be greater in the case of multiple metals, given the electric potential difference induced following contact between different metals (Messer and Wahata, 2002) (Figure 6).

It has been described that the mercury contained in amalgam dental fillings and gold used in alloys for fixed prostheses can give rise to allergic reactions, in the form of lichenoid reactions of the oral mucosa (Koch and Bahmer, 1999, Yiannias et al, 2000, Laine et al, 1997, Evrard and Parent 2010). In a study on 19 patients with lichenoid reactions of the oral mucosa in the vicinity of amalgam fillings (Koch and Bahmer, 1999), it has been shown that 78.9% of patients proved to be sensitized to mercury and that the removal of dental amalgams allowed healing of the mucosal lesions in 86% of cases. In another study on 46 patients with an oral lichen planus (Yiannias et al, 2000), 14 patients had an epicutaneous test positive to gold. In this study, after removal of gold from the mouth, the oral lichen planus disappeared in 10 patients out of 14. Another study on 118 patients with lichenoid lesions in the mouth (Laine et al, 1997), shows that 80 of them had a contact allergy (type IV allergy) to one or more metals: 78 to mercury, 11 to gold, 17 to nickel, 4 to cobalt, 3 to tin, 2 to palladium and 1 to chromium.

All the authors point out that healing of the lesions takes place in a large number of cases after removal of amalgam dental fillings or prostheses containing gold, in the case of a diagnosed contact allergy to mercury or gold (Lygre et al, 2003, Koch and Bahmer, 1999, Yiannias et al, 2000, Laine et al, 1997, Evrard and Parent 2010).

Cobalt is a metal used in alloys in removable or fixed prostheses, and represents a known allergen giving rise to oral manifestations in the case of an allergy (Forte et al, 2008). In a recent study (Warroquier et al, 2009), it has been shown that the burning sensations and intense pruritus on a geographical tongue were due to the cobalt contained in the hook of a removable resin prosthesis replacing a tooth 51 lost through trauma in a 7-year-old child. In this case, type IV allergy had been diagnosed by a positive patch test to cobalt. After removal of the hook containing cobalt, all the patient's signs and symptoms had disappeared.

Burning sensations represent a frequent complaint in patients allergic to one or more dental metals (Alanko et al, 1996). Our team conducted a pilot study to try and establish the prevalence of oral allergies to dental materials in patients complaining of burning sensations of the oral mucosa (Warroquier et al, 2007). In this study, other causes of burning sensations were excluded by a blood test (in order to rule out a metabolic disturbance such as iron, B12 or

folate deficiency), and by swabbing and culture, in order to rule out a fungal infection. Allergy testing revealed that, among that population of 26 “burning mouth” patients, 34.6% were allergic to nickel, 19% to chromium, 11.5% to gold, 11.5% to cobalt and 7.7% to mercury. Only 11.5% of the patients did not display a positive result for an allergy to any of the metals tested. These results are about three times higher than the known percentages of allergies to metals in the general European population, which have been reported to be 20% for nickel, 5.4% for chromium, 6% for gold, 6.5% for cobalt and 2.9% for mercury (Forte et al, 2008).

In a study on 294 patients complaining of both general and local signs (including burning sensations of the oral mucosa), epicutaneous tests have shown an allergy to nickel in 28% of the patients, to gold in 23%, to cobalt in 14%, to palladium in 9% and to mercury in 6% of cases.

All these studies show that the prevalence of allergies to metals in patients presenting signs or symptoms of an oral allergy is higher than the prevalence of allergies in a general European population.

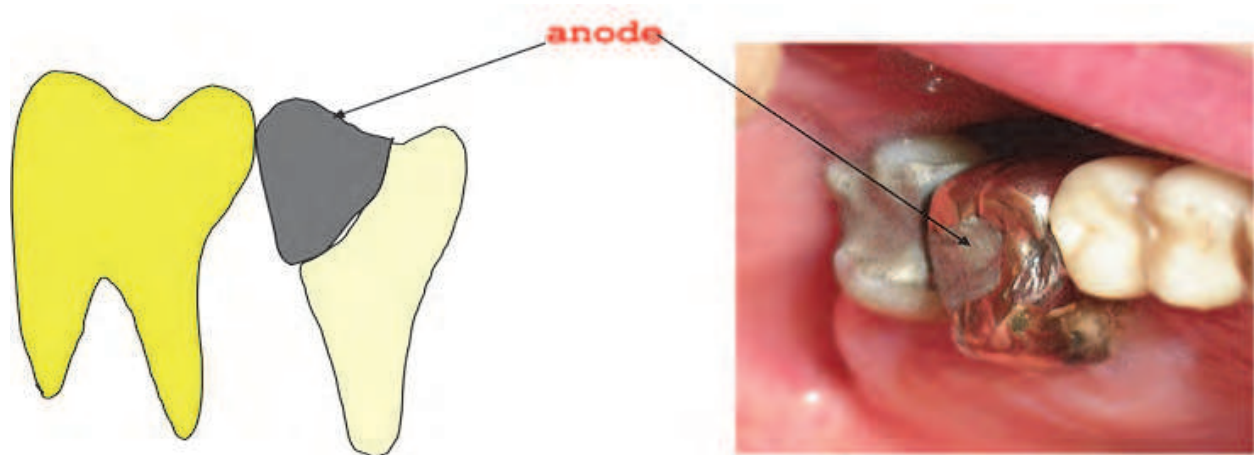


Fig. 6. Multiple metals in contact with each other.

Gold alloy in contact with silver amalgam restoration. The silver amalgam represents the anode pole, and gold alloy the cathode pole. There is an electric potential difference, and electrolytic corrosion within the electrolytic saliva solution may occur.

3. Titanium: a metal allergen of growing significance

Titanium is a metal used in medical and dental fields, because of its properties of strength, corrosion resistance behaviour and excellent biocompatibility due to the formation of an oxide layer on its surface (Steinemann, 2000). In oral and maxillofacial surgery, titanium alloys are used for osteosynthesis plates used in traumatology or maxillofacial surgery, and for dental implants. In implantology, titanium is used most often in the form of “commercially pure” titanium (cpTi: grade I to IV alloys). CpTi contains trace elements (N, C, H, Fe, O, Al, V), that can represent 1% of its volume, and can enhance its mechanical properties and resistance to fracture (Steinemann, 2000, Messer and Wahata, 2002, Geetha et al, 2009). In implantology, titanium is used also in the form of an alloy (grade V titanium): Ti-6Al-4V, Nitinol (Ti-Ni), Ti-Co (Geetha et al, 2009) or titanium-zirconium, especially in cases where narrow implants are recommended (Evrard and Atash, 2009).

The insertion of titanium dental implants can cause internal exposure, and it has been proved that concentrations of 100-300 ppm titanium can be observed in tissues surrounding implants, as well as in regional lymph nodes and pulmonary tissue (Wennerberg et al, 2004). Under unfavourable conditions: acidic pH occurring in a peri-implantitis for example, or excessive mechanical forces on the implant, or close contact of the implant with another metal (amalgam, gold alloy), titanium may corrode and release titanium ions or microparticles of titanium in the area of bone surrounding the implant, which can induce inflammation in affected tissues (Messer and Wataha, 2002). It has been suggested that this mechanism may play a role in loosening orthopaedic endoprotheses (Nakashima et al, 1999), but it has not yet been demonstrated as a factor in the failure of dental implants. Titanium has also been reported to activate macrophages, which may secrete cytokines involved in various disease processes (Muller and Valentine-Thon, 2006). Titanium has a high affinity for proteins, and titanium ions (haptens) released by corrosion may combine with endogenous proteins to form antigenic molecules, captured by Langerhans cells, presented to T-lymphocytes, which in turn can cause the patient to be sensitized to titanium. People are exposed to titanium through environmental sources. Numerous devices such as watches, jewellery and spectacle frames are made of titanium alloy. Most environmental exposure to titanium results from exposure to TiO₂ (E171), which is used in cosmetics such as sunscreens, make-up and deodorants, and in food, medicines or toothpaste. It has been shown that our body can contain a concentration of 50 ppm of titanium (Forte et al, 2008). From then on, sensitization to titanium is possible, through environmental sources, and not necessarily from previous contact with dental implants.

3.1 Allergy to titanium

The first cases in which delayed sensitivity to titanium was suspected, with a local granulomatous reaction, have been described in patients wearing a cardiac pacemaker (Peeters et al, 1984, Yamauchi, 2000). In these cases, the diagnosis of a titanium allergy was made with, respectively, a positive patch test with a little square of the pacemaker placed in artificial perspiration (Peeters et al, 1984), and a positive intra-dermal reaction to an eluate of the surface of the pacemaker (Yamauchi et al, 2000).

More recently, a well documented case of type IV allergy to titanium contained in an osteosynthesis plate inserted for a fracture of the hand was described. The patient had developed eczema on the hand within a few weeks of the insertion of the plate, and an absence of bone healing. A lymphoblastic transformation blood test (LTT) proved positive, although the patch test for TiO₂ was negative. Following the removal of the plate, the LTT gave negative results and the eczema disappeared (Thomas et al, 2006).

Admittedly, it may be difficult to extrapolate results in cases of dental and orthopaedic implants. The skin and the oral mucosa behave differently regarding their potential to develop an allergic reaction (the number of Langerhans cells is greater in skin, the vascular network is more highly developed in the oral mucosa, and the latter is less permeable to antigens). Moreover, implant prosthetic abutments are coated in the mouth with glycoproteins which act as a protective barrier hampering contact between the metal and the mucosa, and the intraosseous contact surface is smaller in dental implants than in orthopaedic ones (Fischer, 2008). In orthopaedic allergy cases, biopsies generally reveal a granulomatous reaction, with numerous macrophages in the vicinity of the prosthesis. This is not the case with dental implants, and different immunological mechanisms may be

involved in the two cases (Messer and Wataha, 2002, Nakashima et al, 1999, Muller and Valentine-Thon, 2006).

The case of a patient with facial eczema suggestive of type IV allergy to titanium following the placement of a mandibular dental implant has been reported (Egusa et al, 2008). In this case, an allergy to titanium was diagnosed by the combination of clinical signs (appearance of eczema within a few weeks of implant placement), and a positive blood test (LTT). The diagnosis of allergy to titanium was confirmed by the disappearance of eczema following removal of the implants.

More recently, it has been demonstrated that clinically-relevant hypersensitivity to titanium can occur following exposure to titanium (Muller and Valentine-Thon, 2006). In that study, 56 patients had developed severe health problems (muscle and joint pain, chronic fatigue syndrome, neurological problems, depression, or acne-like facial inflammation) after receiving Ti-based dental implants, orthodontic braces or endoprostheses. The authors used the MELISA test, which had proved effective in the diagnosis of hypersensitivity to metals (Stejskal et al, 1994), as well as patch tests. Of the 56 patients tested with MELISA, 37.5% were positive, 28.5% ambiguous and 33.9% negative to titanium. Among the 33.9% negative to titanium, 57.9% showed lymphocyte reactivity to nickel or other metals. All 54 patch-tested patients were negative to titanium. Following removal of the implants, a remarkable clinical improvement was noticed and among the 15 retested patients this clinical improvement correlated with normalisation of MELISA reactivity.

In a prospective study over a three-year period (Sicilia et al, 2008), 1500 patients with dental implants were monitored. In that study, an allergy to titanium was diagnosed on the basis of clinical signs of an allergy appearing following implant placement, or on the basis of an unexplained failure of the implant, and a patch test positive for titanium, tested in the form TiO₂, or for a titanium metal powder in aqueous solution. The results of this study show that 0.6% (1/800) of patients with dental implants have a patch-test positive for titanium, but 0% (0/35) of the patients without implants have this result. The epicutaneous tests are positive in 50% (8/16) and 62.8% (5/8) of the patients who show signs, respectively, of an allergy following implant placement, and unexplained early failure of one or more implants. In patients having allergies to one or more metals (nickel, chromium, cobalt, gold or mercury), 5.3% (1/19) have a patch test positive for titanium. It should be noted that the authors do not report the characteristics of the titanium in their patients (titanium alloy or commercially pure titanium?). The rate of corrosion is higher with titanium-aluminium-vanadium implants, which may have an influence on the prevalence of allergic reactions.

All these reports reflect the difficulty in evaluating suspected titanium hypersensitivity. It is known that the epicutaneous tests used in the diagnosis of an allergy to titanium are still not very sensitive, and there is no standardized valid patch-test preparation for this. Moreover, the lack of concordance between the results of patch-tests and blood tests (MELISA) is illustrated in the above study (Muller and Valentine-Thon, 2006). Given the difficulties of diagnosing a titanium allergy, studies probably underestimate the true prevalence of titanium allergies in patients having dental implants.

3.2 Diagnosis of a titanium allergy

The above studies demonstrate that titanium can induce clinically relevant hypersensitivity and other immune dysfunctions in certain patients chronically exposed to this metal. Titanium should no longer, therefore, be considered biologically inert. In implantology, it is reasonable to say that allergy testing for titanium is indicated in some cases.

3.2.1 Before implant placement

It has been shown that many patients suffer from multiple allergies (Forte et al, 2008), and that people with a history of allergy to metals or jewellery have a greater risk of developing a hypersensitivity reaction to a metal implant (Hallab et al, 2001).

Furthermore, although titanium allergy has a low prevalence rate, for patients with a previous history of allergies, it may be advisable to carry out a metal allergy assessment and allergy testing before placing permanent implants, in order to avoid a failure of the implant due to an allergic reaction to titanium.

3.2.2 After implant placement

The failure of implants has been widely studied, and the main causes of dental implant failure are infection and overload (Esposito et al, 1999a, 1999b, 1999c). However, some failures are difficult to explain, such as spontaneous rapid exfoliation of the implant, or the successive failure of implants in the same patients, known as “cluster phenomenon”, without any infection or overload risk factor identified. Authors agree that in these cases, there must be a systemic determinant of failure that has not been identified or understood (Wood and Vermilyea, 2004, Chuang, 2005).

An allergic reaction can be reasonably suspected after dental implant placement, on the basis of signs or symptoms associated with allergy, such as rash, urticaria, pruritus, swelling in the orofacial region, oral or facial erythema, eczematous lesions of the cheeks, or hyperplastic lesions of soft tissue (the peri-implant mucosa) (Mitchel et al, 1990). In these cases, allergy testing should be performed.

3.2.3 Tests available for the diagnosis of an allergy to titanium

As described in chapter 3.2, there is no consensus on how a sensitization and/or allergic reaction to titanium should be explored. It is also difficult to compare the results from different studies related to titanium allergies, because some refer to the use of patch tests, while others use prick tests and/or blood tests (LTT, MELISA) (Sicilia et al, 2008, Valentine-Thon et al, 2006).

To date, no standard patch test for titanium has so far been developed, and positive reactions to titanium have only rarely been demonstrated with skin testing (Forte et al, 2008).

The sensitivity of patch tests has been shown to be about 75% for type IV metal allergy. Some authors have suggested that 0.1% and 0.2% titanium sulphate solution and 0.1% and 0.2% titanium chloride are successful reagents for the skin-patch tests and could be a valuable alternative to the titanium oxide normally used for patch testing (Okamura et al, 1999), but so far no study related to dental implants allergies has used the method.

The MELISA test has been validated to detect sensitization to titanium and other metals (Sjekstal et al, 1999, Muller and Valentine-Thon 2006), but there can be some lack of specificity in lymphocyte proliferation.

It would be valuable to have a sensitive and specific test that could help in the diagnosis of titanium sensitization or allergy.

3.2.4 Future prospects in the diagnosis of sensitization or allergy to titanium

Interleukin-17 and Interleukin-22 are produced by a subset of a recently defined T-cell line, known as Th-17. IL-17 has been associated with many inflammatory diseases in humans, including rheumatoid arthritis, organ rejection and asthma. It has been showed that the

number of Th-17 cells and the expression of IL-17 was significantly increased in positive patch test biopsies, regardless of the nature of the antigen (Oboki et al, 2008, Zhao et al, 2009, Larsen et al, 2009).

IL-22 is a critical mediator in mucosal host defence, which has complex pro-inflammatory and anti-inflammatory and autoimmune effects. It has been shown that patients with contact dermatitis to nickel had a significantly higher IL-22 blood level, compared with control (Ricciardi et al, 2009), indicating a possible involvement of IL-22 in the pathogenesis of human allergic contact dermatitis.

It would be interesting to develop a blood test, based on the measurement of the production of IL-17 and/or IL-22 by lymphocytes, in order to be able to diagnose with certainty a sensitization to titanium.


Our team is currently trying to develop a technique, using flow cytometry, for the purpose of detecting the activation of lymphocytes stimulated by a metal, and measuring different mediators (cytokines, inflammatory mediators) released in response to the metal.

4. References

- Alanko K., Kanerva L., Jolanki R., Kannas L. & Estlander T. *Oral mucosal diseases investigated by patch testing with a dental screening series*. Contact Dermatitis, 1996; 34 (4):263-267.
- Axell T. *Hypersensitivity of the oral mucosa: clinics and pathology*. Acta Odontol. Scand. 2001, 59:315-319.
- Chuang S., Cai T., Douglass C., Wei L. & Dodson T. *Frailty approach for the analysis of clustered failure time observation in dental research*. J.Dent Res., 2005; 84: 54-58.
- Egusa H., Ko N., Shimazu T. & Yatani H. *Suspected association of an allergic reaction with titanium dental implants: a clinical report*. J. Prosthet Dent. 2008, 100: 344-7.
- Esposito M., Hirsch J., Lekholm U. & Thomsen P. *Differential diagnosis and treatment strategies for biologic complications and failing oral implants: a review of the literature*. Int J. Oral Maxillofac. Impl. 1999; 14: 473-90.
- Esposito M., Lausmaa J., Hirsch J. & Thomsen P. *Surface analysis of failed oral titanium implants*. J. Biomed. Mater. res. 1999; 48: 559-68.
- Esposito M., Thomsen P., Ericson L. & Lekholm U. *Histopathologic observations on early oral implant failures*. Int J Oral Maxillofac Impl. 1999, 14: 798-810
- Evrard L. & Atash R. *Restauration de l'édentation complète mandibulaire dans le cas d'une crête osseuse fine, à l'aide de deux implants de faible diamètre en alliage Titane-Zircone stabilisant une prothèse en résine par l'intermédiaire de deux attachements Locator*. Dentist News, 2009, 19: 14-19
- Evrard L., Waroquier D. & Parent D. *Allergies to dental metals. Titanium: a new allergen*. Rev. Med. Brux. 2010, 31: 44-9
- Evrard L. & Parent D. *Oral allergies to dental materials. Review of the literature and report of three cases*. Bull. Group Int Rech Stomatol. Odontol., 2010; 49: 14-19
- Fischer 's. *Allergy*. Eds. Springer-Verlag. 2008: 684-5.
- Forte G., Petrucci F. & Bocca B. *Metal allergens of growing significance: epidemiology, immunotoxicology, strategies for testing and prevention*. Inflammation and Allergy, 2008, 7: 1-18

- Garhammer P., Schmalz G., Hiller K., Reitingner T. & Stolz W. *Patients with local adverse effects from dental alloys: frequency, complaints, symptoms, allergy*. Clin. Oral Invest. 2001;5:240-249.
- Gawkrodger D J. *Investigation of reactions to dental materials*. Br. J. Dermatol. 2005; 153:479-485.
- Geetha M., Singh AK., Asokamani R. & Gogia AK. *Ti based biomaterials, the ultimate choice for orthopedic implants – A review*. Prog Mater Sci, 2009, 10: 1-29
- Gell P. & Coombs R., *The classification of allergic reactions underlying disease*. In: R.R.A. Coombs and P.G.H. Gell, Editors, *Clinical Aspects of Immunology*, Blackwell Science (1963).
- Grevers G. & Röcken M. *Atlas de poche d'allergologie*. 2002. Flammarion Médecine-Sciences.
- Axell T. *Hypersensitivity of the oral mucosa: clinics and pathology*. Acta Odontol. Scand. 2001;59:315-319.
- Hallab M., Mikecz K., Vermes C., Skipor A. & Jacobs J. *Differential lymphocyte reactivity to serum-derived metal-protein complexes produced from cobalt-based and titanium-based implant alloy degradation*. J. Biomed Mater. Res. 2001; 56: 427-36.
- Koch P. & Bahmer F. *Oral lesions and symptoms related to metals used in dental restorations: A clinical, allergological, and histological study*. J. Am. Acad. Dermatol. 1999; 41:422-430.
- Laine J., Kalimo K. & Happonen RP. *Contact allergy to dental restorative materials in patients with oral lichenoid lesions*. Contact Dermatitis. 1997;36:141-146.
- Larsen J., Bonefeld C., Poulsen S. & Geisler C. *IL-23 and IL-17-mediated inflammation in human allergic contact dermatitis*. J Allergy Clin Immunol. 2009; 123: 486-492
- Leigh AS., Fowler JR., Morgan W. & Looney SW. *Dental metal allergy in patients with oral, cutaneous and genital lichenoid reactions*. Am. J. Contact Dermatitis. 2001;12 (3):146-150.
- LeSueur BW. & Yiannias AJ. *Contact stomatitis*. Dermatol. Clin 2003;21:105-114.
- Yiannias JA., el-Azhari RA., Hand JH., Pakzad SY. & Roger RS. *Relevant contact sensitivities in patients with the diagnosis of oral lichen planus*. J. Am Acad. Dermatol. 2000;42:177-182.
- Lygre G. B., Gjerdet N. R., Grønningstraeter A. G. & Björkman L. *Reporting on adverse reactions to dental materials: intraoral observations at a clinical follow-up*. Community Dent Oral Epidemiol. 2003;31:200-206.
- Messer & Wahata. *Dental materials: biocompatibility*. In *Encyclopedia of Materials: Science and Technology*. 2002. ISBN: 0-08-043152-6. pp 1-10
- Müller K. & Valentine-Thon E. *Hypersensitivity to titanium: clinical and laboratory evidence*. Neuro Endocrinol Lett, 2006, 27: 31-35
- Nakashima Y., Sun D., Trindade M., Maloney W., Goodman S. & Schurman D. *Signaling pathways for tumor necrosis – α and interleukin-6 expression in human macrophages exposed to titanium alloy particulate debris in vitro*. J Bone Joint Surg. 1999; 81: 603-15.
- Oboki K., Ohno T., Saito H. & Nakae S. *Th17 and allergy*. Allergy International. 2008; 57: 121-134
- Okamura T., Morimoto M., Fukushima D. & Yamane G. J Dent res. 1999; 78: 1135.
- Peeters MS., Schroeter AL., Van Hale HM., Broadbent JC. *Pacemaker contact sensitivity*. Contact Dermatitis, 1984, 11:218-218

- Ricciardi L., Minciullo P., Saitta P., Trombetta D., Saija A. & Gangemi S. *Increased serum levels of IL-22 in patients with nickel contact dermatitis*. *Contact Dermatitis*. 2009; 60: 57-58
- Scully C. *Oral and Maxillofacial Medicine*. Ed Elsevier, Edinburgh; 2004, ISBN 0723610746, PP194-204.
- Sicilia A., Cuesta S., Coma G., Guisasola C., Ruiz E. & Maestro A. *Titanium allergy in dental patients: a clinical study on 1500 consecutive patients*. *Clin. Oral Implants Res*; 2008, 19: 823-35.
- Steinemann S. *Titanium – the material of choice?* *Periodontology*; 2000; 17: 7-21.
- Stejskal V., Cederbrant K., Lindvall A., Forsbeck M. & MELISA- *An in vitro tool for the study of metal allergy*. *Toxicol in vitro*. 1994; 8: 991-1000.
- Thomas P., Brandl W., Majer S., Summer B. & Przybilla B. *Hypersensitivity to titanium osteosynthesis with impaired fracture healing, eczema and T-cell hyperresponsiveness in vitro: case report and review of the literature*. *Contact Dermatitis*, 2006, 55: 199-202.
- Vamnes J., Lygre G., Grønningstraeter A. & Gjerdet N. *Four years of clinical experience with an adverse reaction unit for dental biomaterials*. *Comm. Dent. Oral Epidemiol*. 2004;32:150-157.
- Waroquier D., Evrard L., Nelis M. & Parent D. *Allergic contact dermatitis presenting as geographical tongue with pruritus*. *Contact Dermatitis*. 2009; 60: 106-119.
- Waroquier D., Evrard L., Flamme M. & Parent D. *Apport des tests épicutanés dans la mise au point des stomatodynies*. *Bull du GERDA*, 2007
- Wennerberg A., Ide-Ektessabi A., Hatkamata S., Sawase T., Johansson C., Albrektsson T., Martinelli A., Sodervall U. & Odelius H. *Titanium release from implants prepared with different surface roughness*. 2004. *Clin. Oral Impl. Res*. 15: 505-512.
- Wood M., Vermilyea S. *A review of selected dental literature on evidence-based treatment planning for dental implants: reports of the committee on research in fixed prosthodontics of the academy of fixed prosthodontics*. *J Prosthetic Dentistry*. 94: 447-462.
- Yamauchi R., Morita A., Tsuji T. *Pacemaker dermatitis from titanium*. *Contact Dermatitis*, 2000, 42: 52-53
- Zhao Y., Balato A., Fischelevich R., Chapoval A., Mann D. & Gaspari A. *Th17/Tc17 infiltration and associated cytokine gene expression in elicitation phase of allergic contact dermatitis*. *British J Dermatol*; 2009, 161: 1301-1306



Implant Dentistry - A Rapidly Evolving Practice

Edited by Prof. Ilser Turkyilmaz

ISBN 978-953-307-658-4

Hard cover, 544 pages

Publisher InTech

Published online 29, August, 2011

Published in print edition August, 2011

Implant dentistry has come a long way since Dr. Branemark introduced the osseointegration concept with endosseous implants. The use of dental implants has increased exponentially in the last three decades. As implant treatment became more predictable, the benefits of therapy became evident. The demand for dental implants has fueled a rapid expansion of the market. Presently, general dentists and a variety of specialists offer implants as a solution to partial and complete edentulism. Implant dentistry continues to evolve and expand with the development of new surgical and prosthodontic techniques. The aim of Implant Dentistry - A Rapidly Evolving Practice, is to provide a contemporary clinic resource for dentists who want to replace missing teeth with dental implants. It is a text that relates one chapter to every other chapter and integrates common threads among science, clinical experience and future concepts. This book consists of 23 chapters divided into five sections. We believe that, Implant Dentistry: A Rapidly Evolving Practice, will be a valuable source for dental students, post-graduate residents, general dentists and specialists who want to know more about dental implants.

How to reference

In order to correctly reference this scholarly work, feel free to copy and paste the following:

Laurence Evrard (2011). Titanium: A New Allergen, Implant Dentistry - A Rapidly Evolving Practice, Prof. Ilser Turkyilmaz (Ed.), ISBN: 978-953-307-658-4, InTech, Available from:

<http://www.intechopen.com/books/implant-dentistry-a-rapidly-evolving-practice/titanium-a-new-allergen>

INTECH
open science | open minds

InTech Europe

University Campus STeP Ri
Slavka Krautzeka 83/A
51000 Rijeka, Croatia
Phone: +385 (51) 770 447
Fax: +385 (51) 686 166
www.intechopen.com

InTech China

Unit 405, Office Block, Hotel Equatorial Shanghai
No.65, Yan An Road (West), Shanghai, 200040, China
中国上海市延安西路65号上海国际贵都大饭店办公楼405单元
Phone: +86-21-62489820
Fax: +86-21-62489821

© 2011 The Author(s). Licensee IntechOpen. This chapter is distributed under the terms of the [Creative Commons Attribution-NonCommercial-ShareAlike-3.0 License](https://creativecommons.org/licenses/by-nc-sa/3.0/), which permits use, distribution and reproduction for non-commercial purposes, provided the original is properly cited and derivative works building on this content are distributed under the same license.

IntechOpen

IntechOpen